

HIGH TIBIAL OSTEOTOMY

Patient Specific Template



High Tibial Osteotomy

Patient Details:

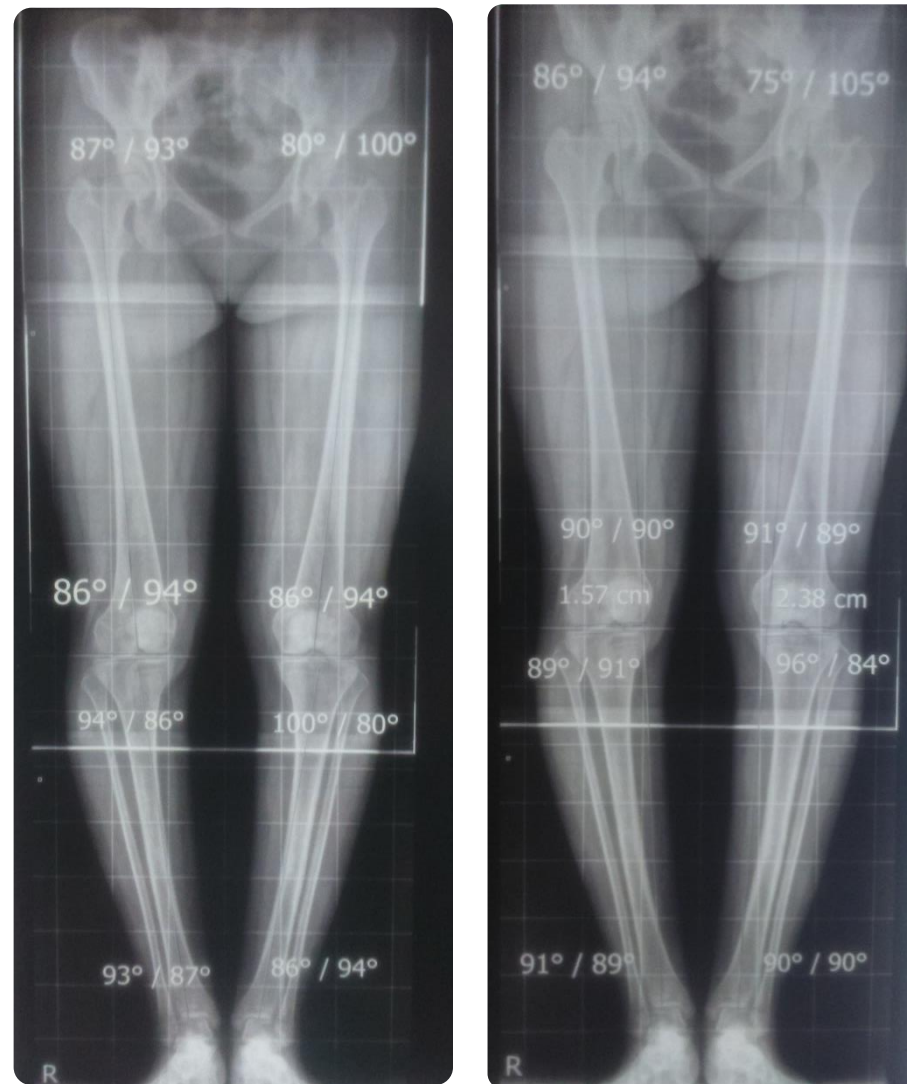
Sex: Female

Age: 24 years

High Tibial Osteotomy

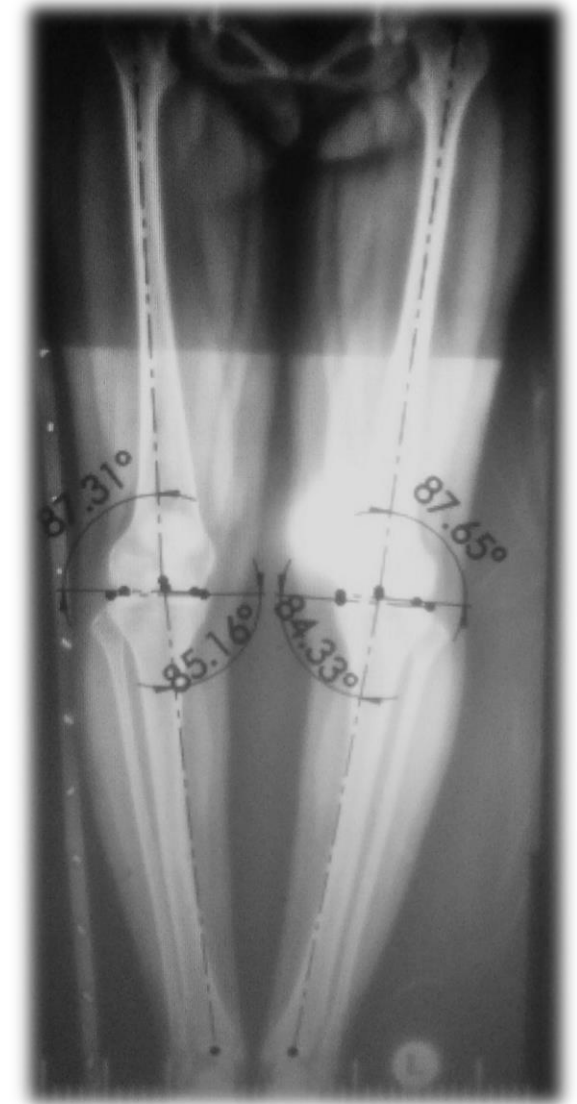
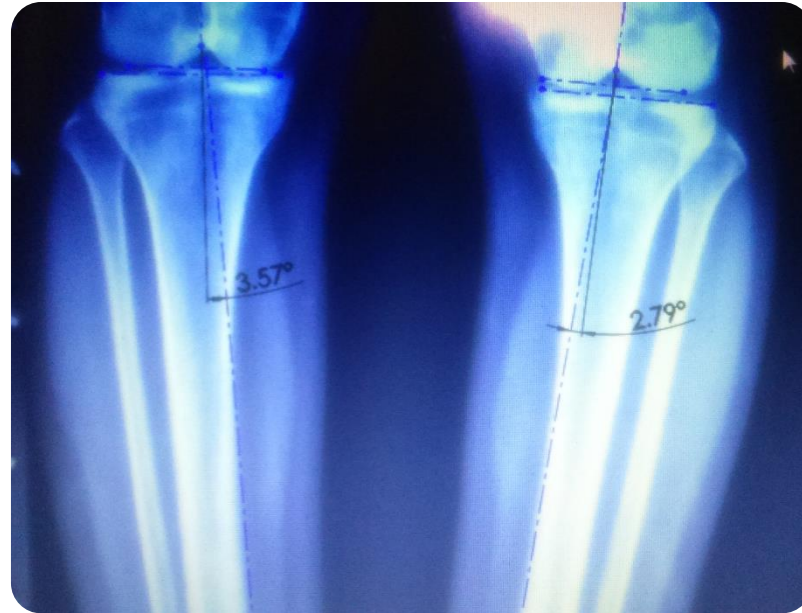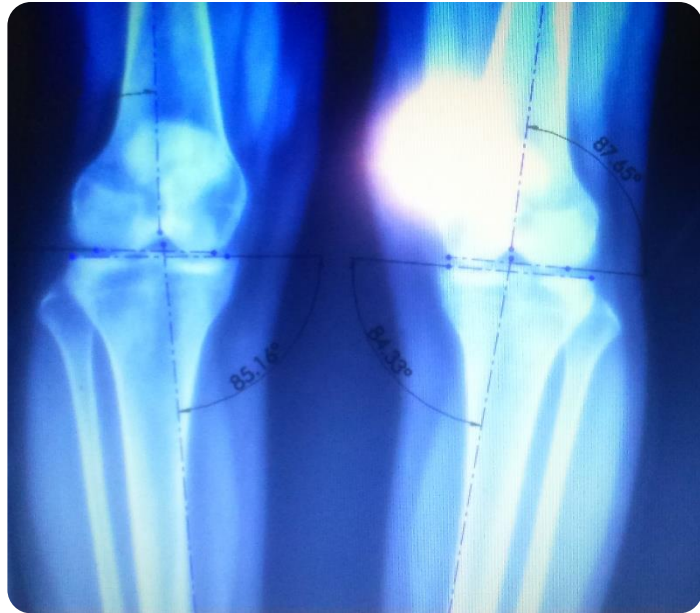High Tibial Osteotomy

Preoperative CT scan



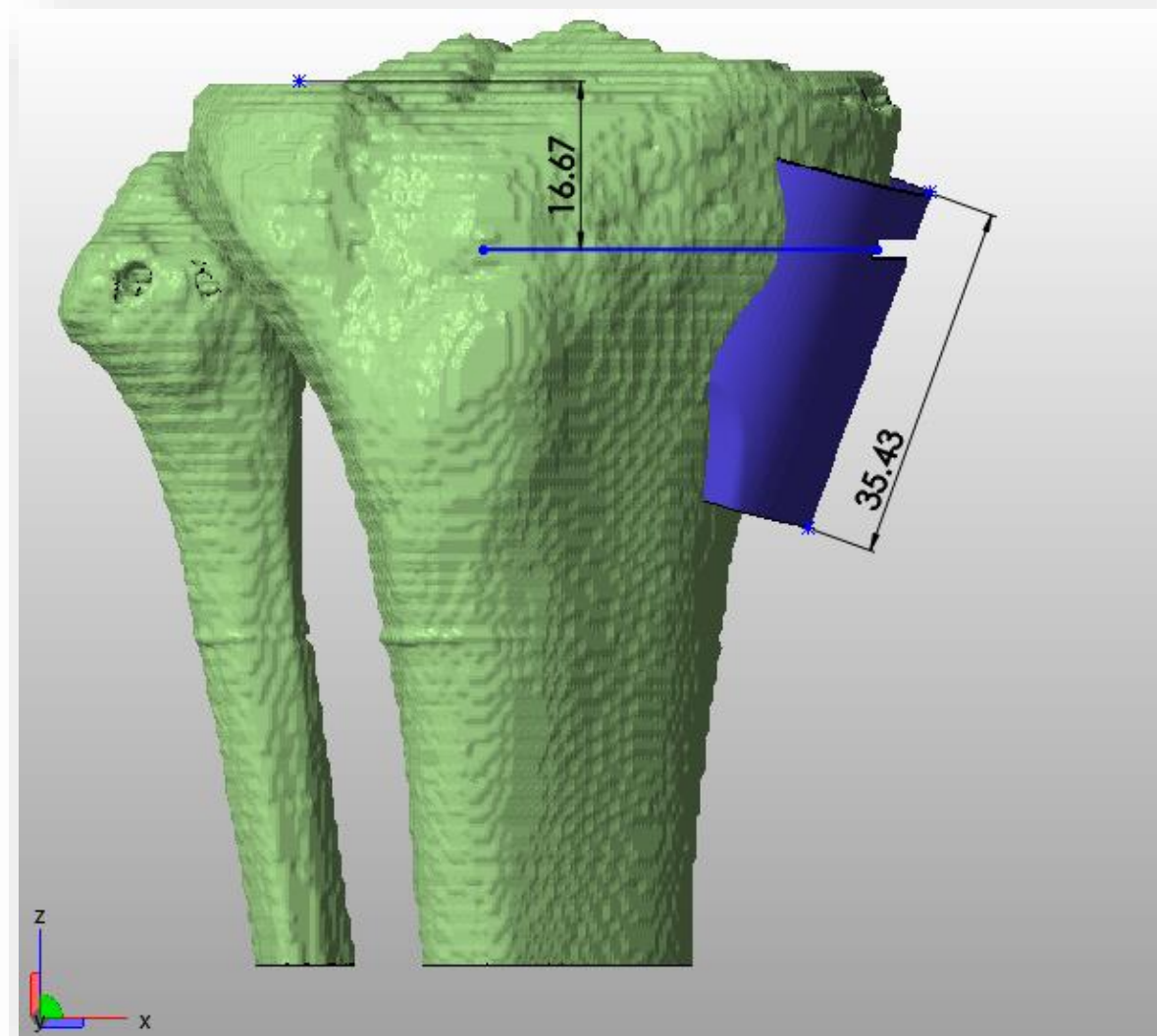
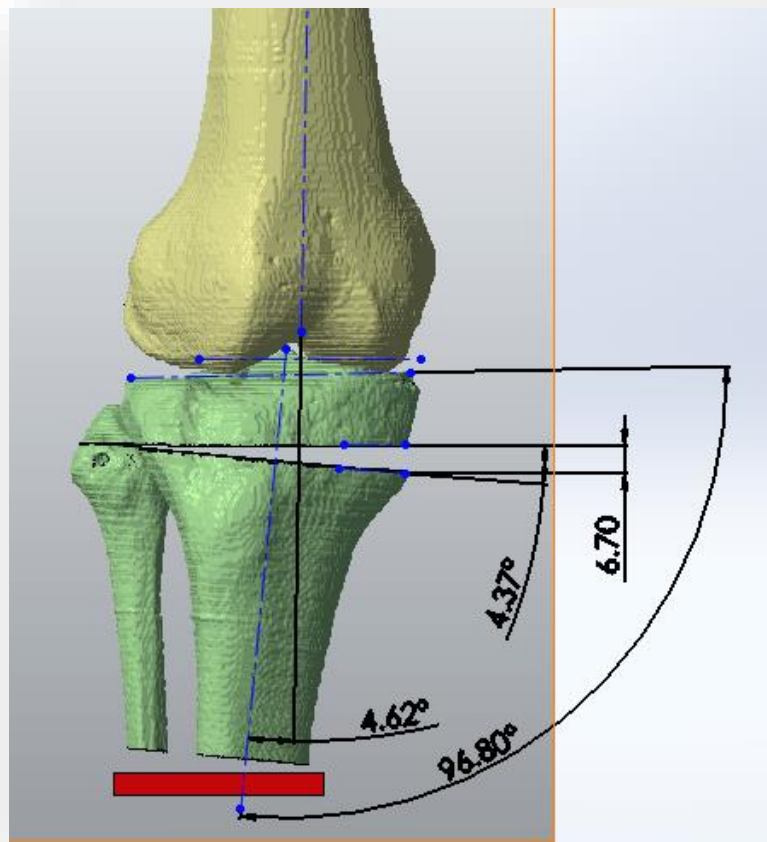
©2015 SurgiNovi. All rights reserved

High Tibial Osteotomy



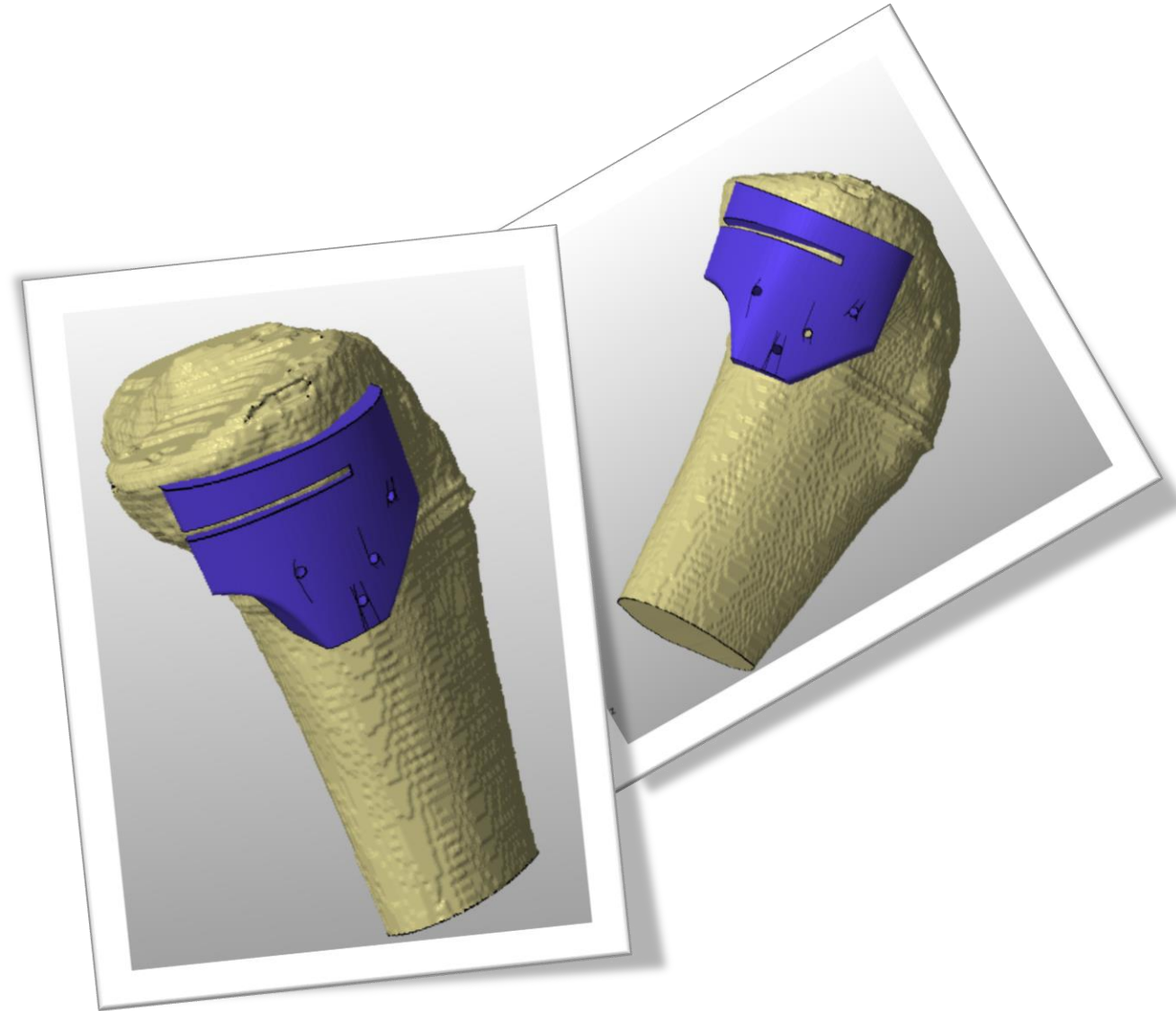
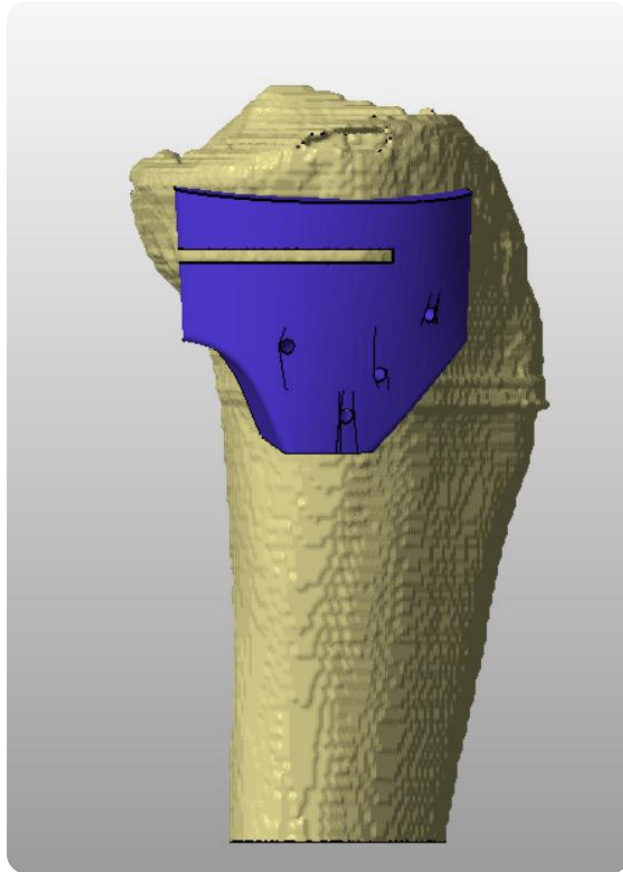
©2015 SurgiNovi. All rights reserved

High Tibial Osteotomy



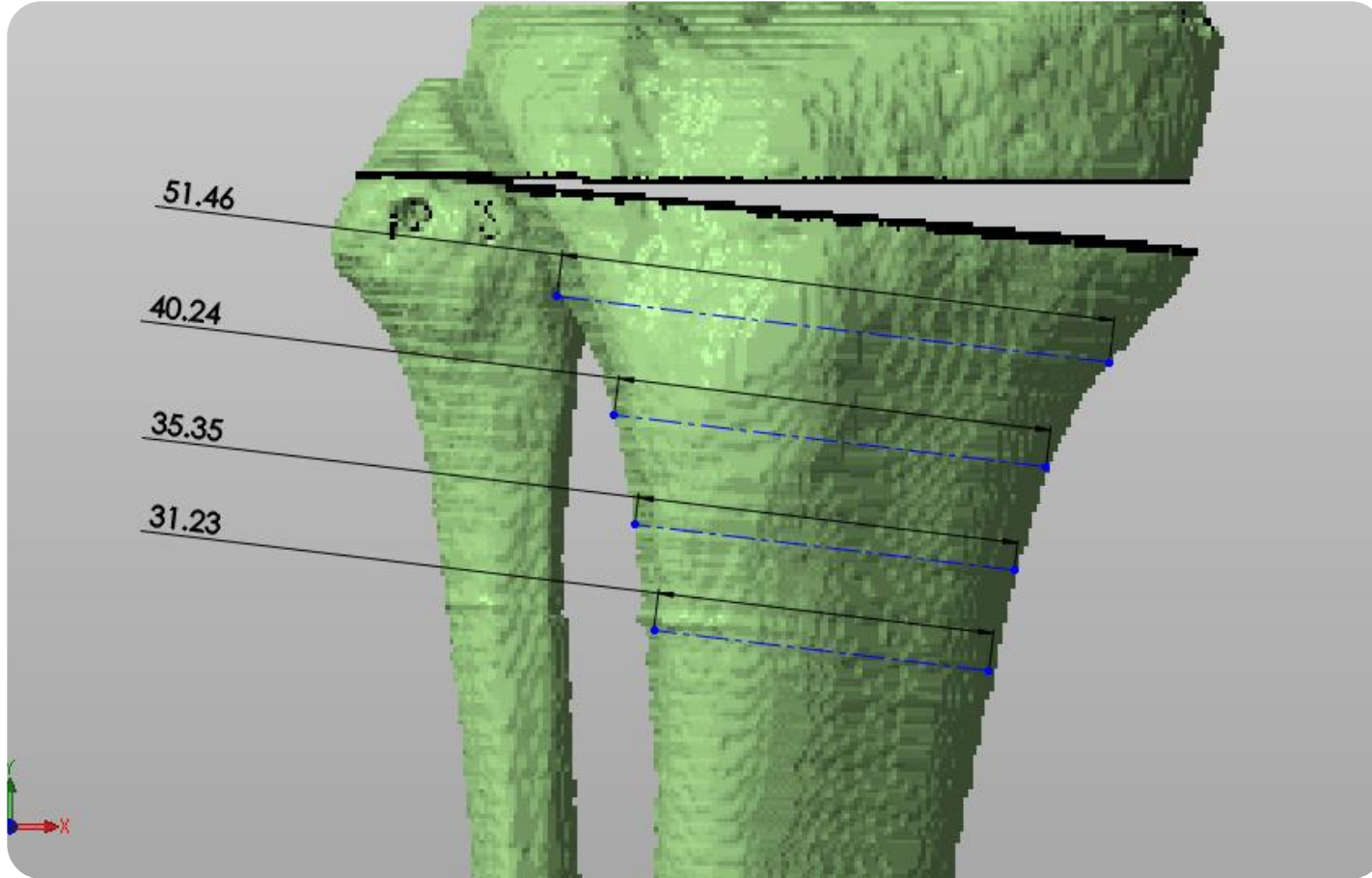
©2015 SurgiNovi. All rights reserved

High Tibial Osteotomy

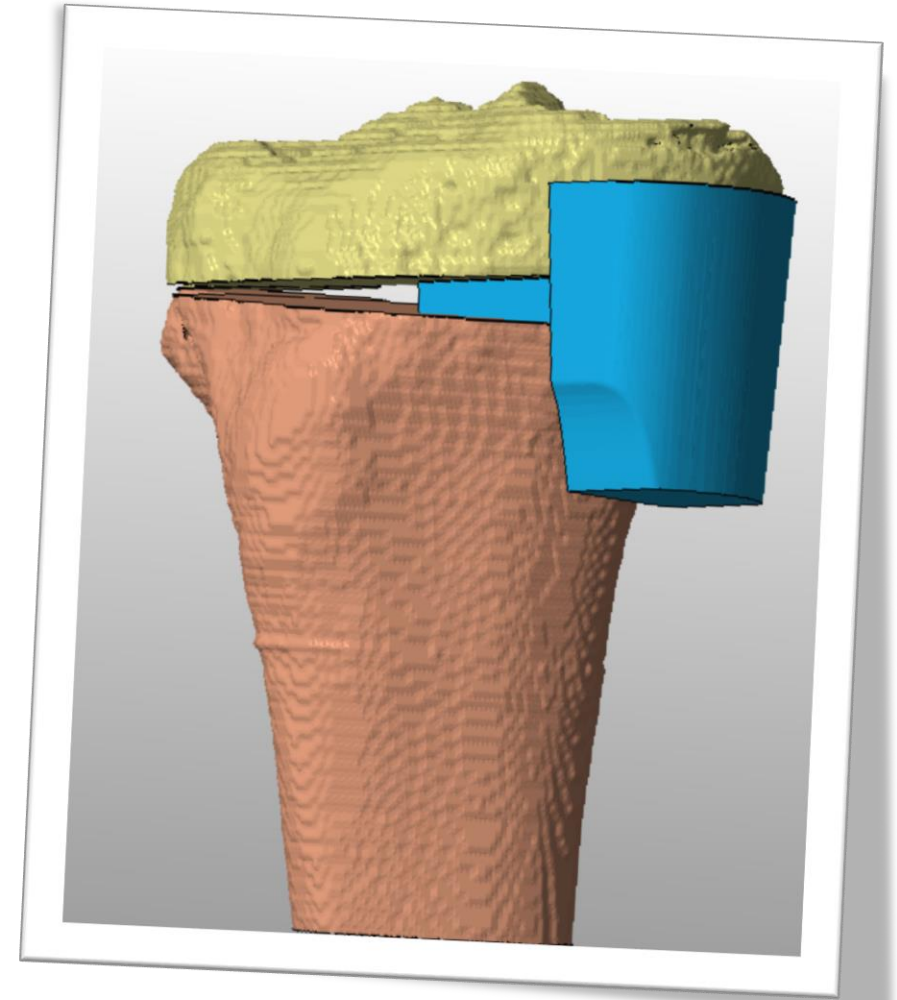



©2015 SurgiNovi. All rights reserved

High Tibial Osteotomy

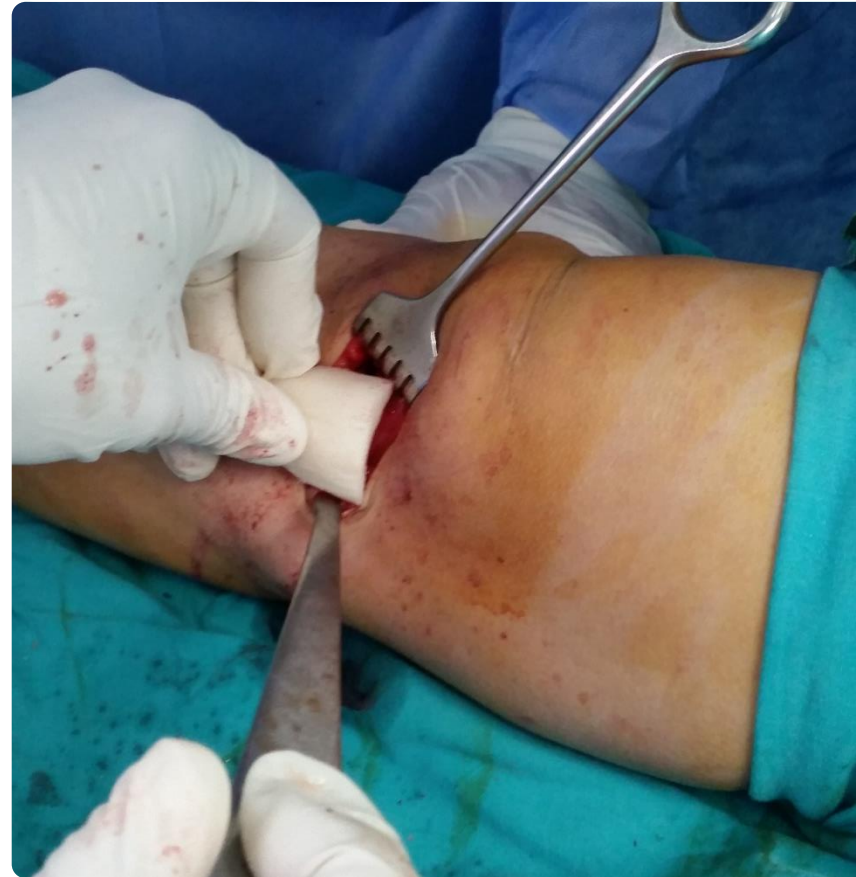
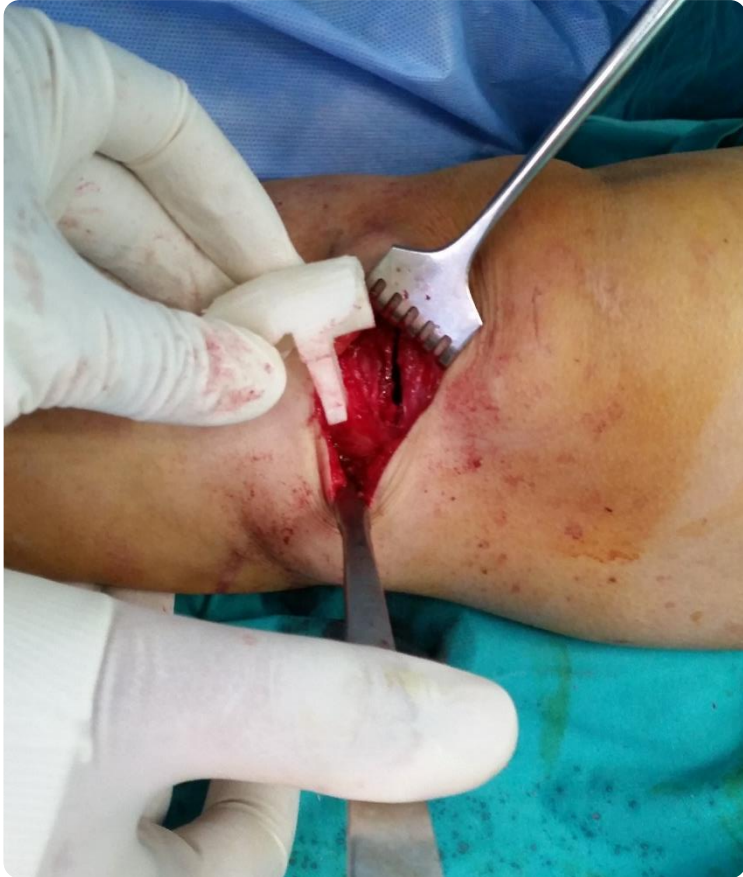
High Tibial Osteotomy



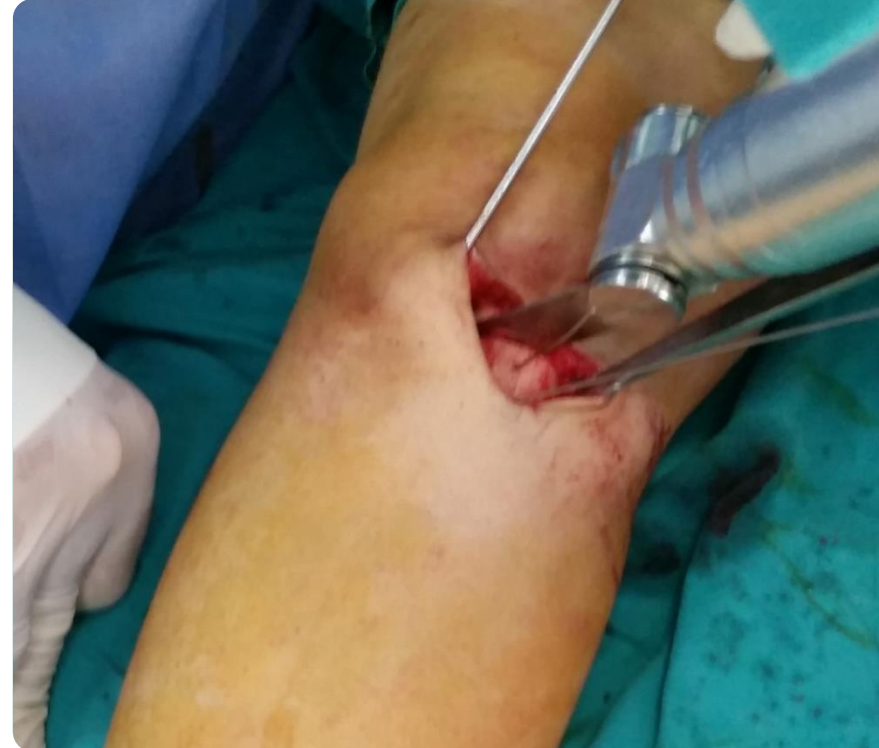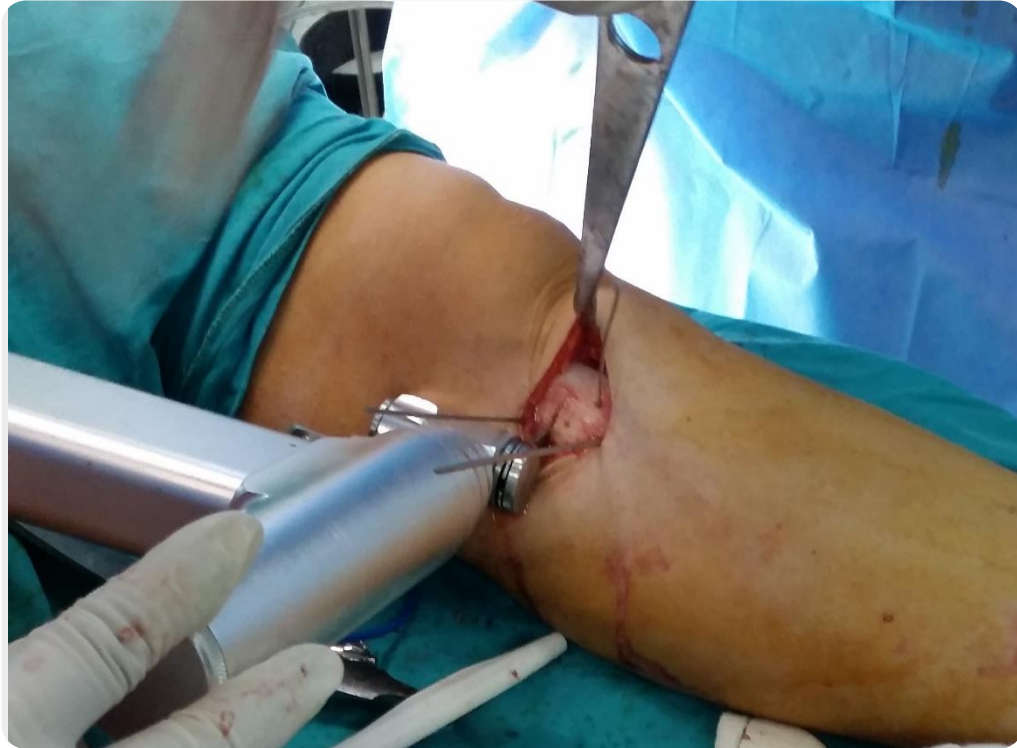©2015 SurgiNovi. All rights reserved

High Tibial Osteotomy



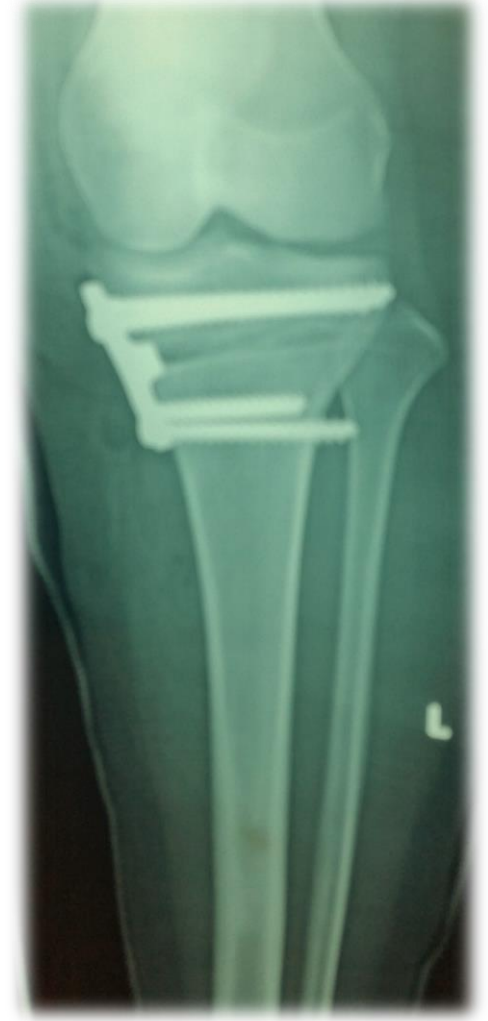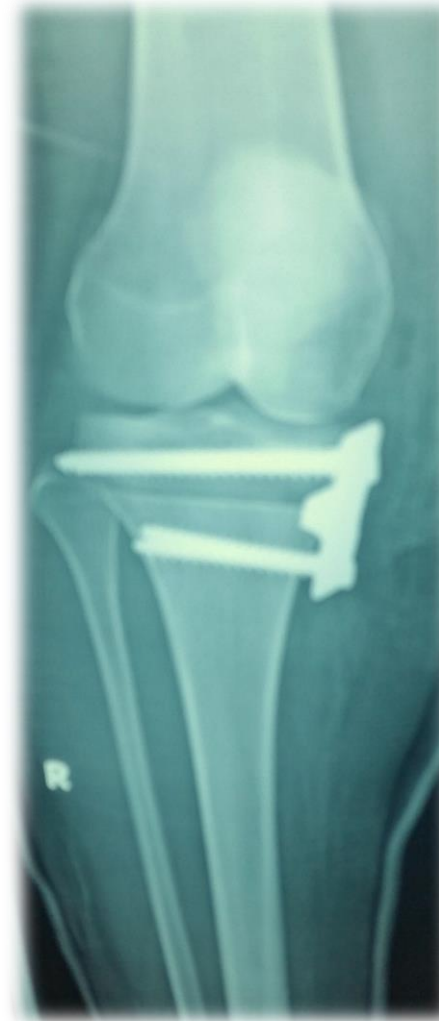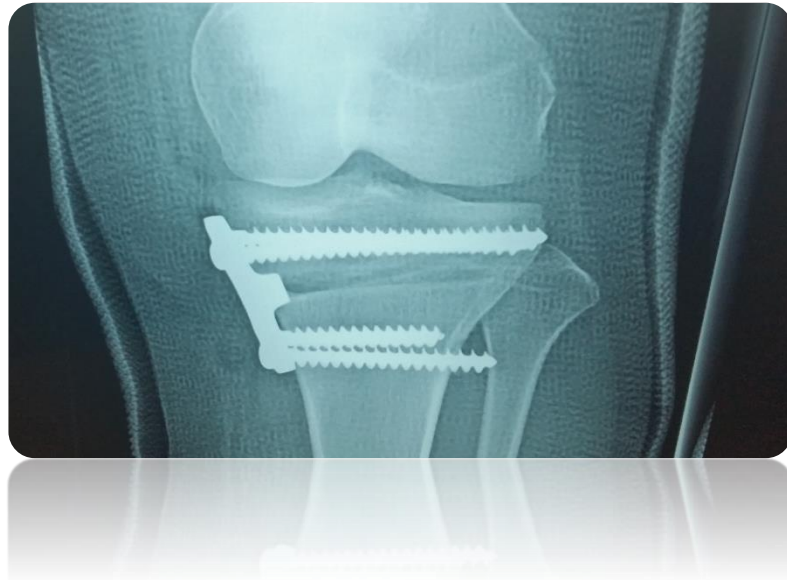
©2015 SurgiNovi. All rights reserved

High Tibial Osteotomy

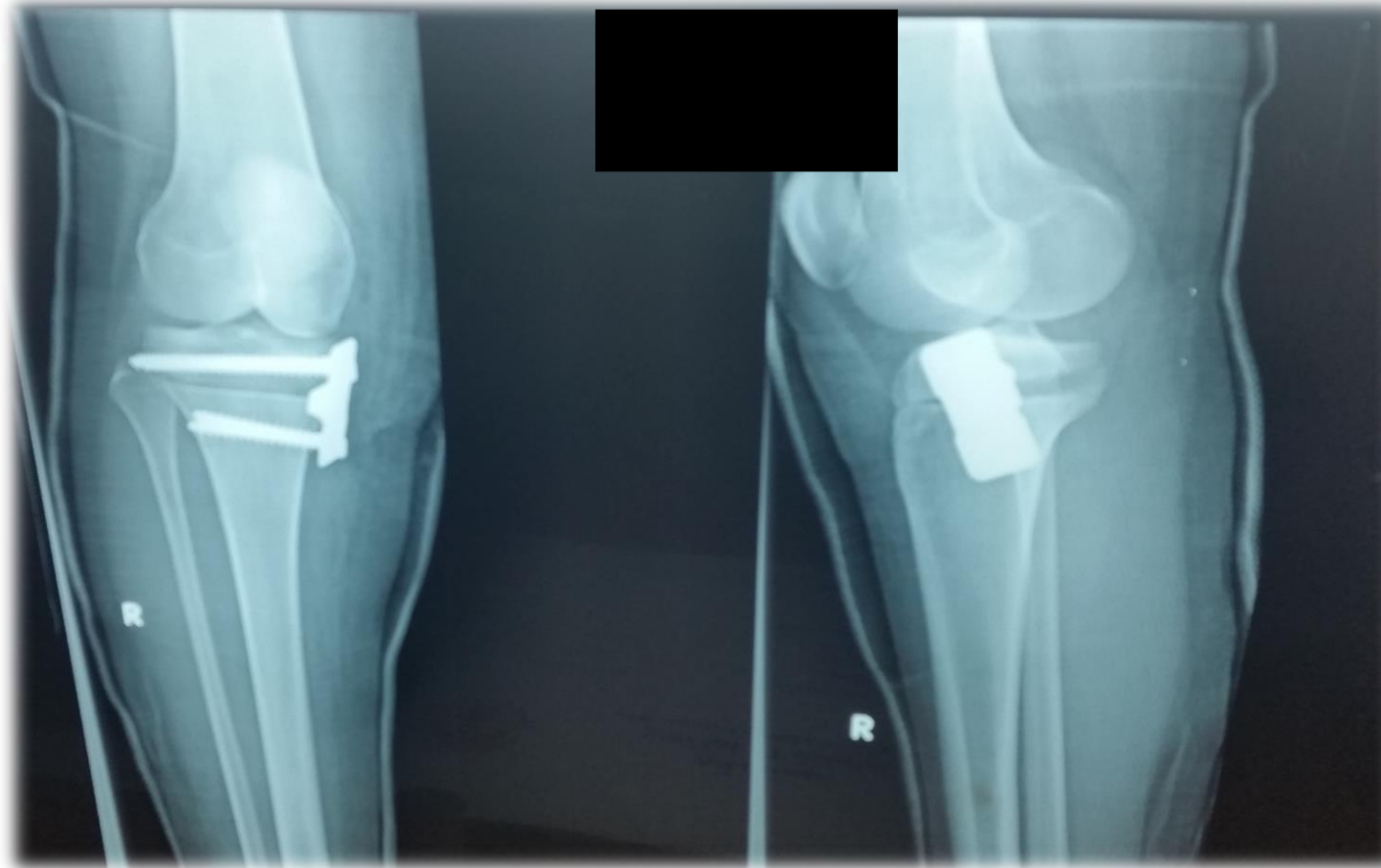


©2015 SurgiNovi. All rights reserved

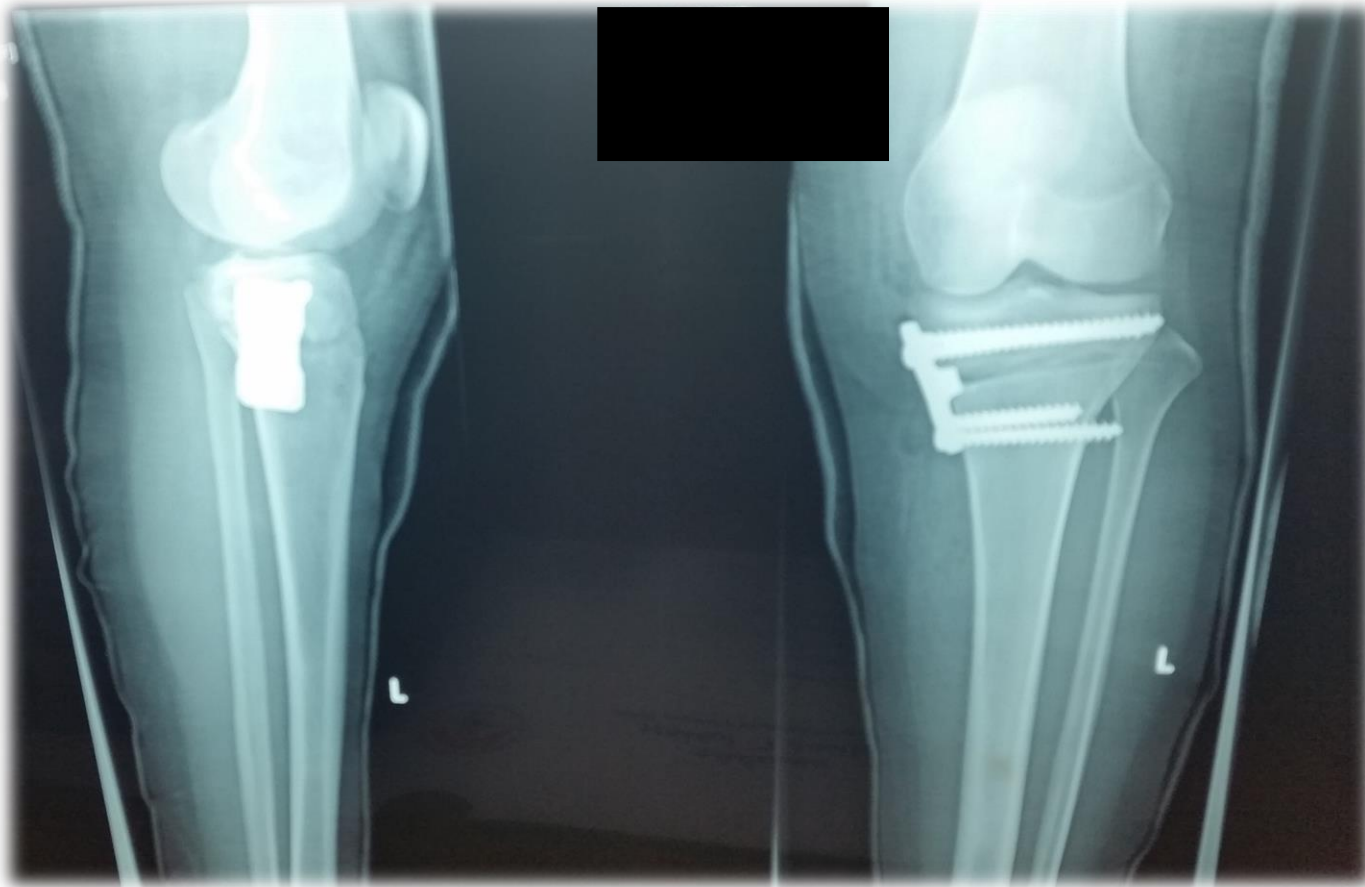
High Tibial Osteotomy



High Tibial Osteotomy



High Tibial Osteotomy



©2015 SurgiNovi. All rights reserved